



RESENTING CLINICAL SIGNS

History: Grade II/VI murmur and irregular heart rhythm noted during exam on 6/18/22. No current medications.

DATE

6/24/22

ECHOCARDIOGRAPHIC FINDINGS

2D, M-mode, and Doppler study.

PERFORMED BY:

Shari Reffi, CVT

INTERPRETED BY

Keith Blass, DVM,
MS, DACVIM
(Cardiology)

Left atrial size is normal. The mitral valve leaflets are mildly thickened, and a mild jet of mitral regurgitation is present. Left ventricular dimensions are normal, as is left ventricular systolic function. The aorta and aortic valve are normal. Right atrial and right ventricular dimensions are normal. The tricuspid valve leaflets are mildly thickened, and a mild jet of tricuspid regurgitation is present. TR velocity does not suggest the presence of pulmonary hypertension. The pulmonary artery and pulmonic valve are normal. No shunting lesions are visualized. No pericardial effusion or cardiac masses are seen.

PATIENT

Bud Lessing

LA - 33.1 mm
LVIDd - 32.8 mm
LVIDs - 20.0 mm
FS - 39%
RA - 20.7 mm
LVOT - 1.00 m/s
RVOT - 0.84 m/s
TR - 2.44 m/s

SPECIES

Canine

ASSESSMENT/RECOMMENDATIONS

Degenerative mitral and tricuspid valve disease

BREED

Terrier Mix

This examination demonstrates mild regurgitation of blood across Bud's mitral and tricuspid valves resulting from degenerative valve disease. The hemodynamic effects of each of the regurgitations also appear to be mild, as Bud does not have secondary dilation of any of his cardiac chambers, and his ventricular systolic function is normal. As such, Bud's valvular diseases appear to be well-compensated, and his current risk for the development of clinical signs secondary to them, such as coughing, exercise intolerance, syncope, and labored breathing, appears to be low.

SEX

No therapy is recommended at this stage of Bud's valvular diseases.

MN

An ECG is recommended to further evaluate Bud's irregular heart rhythm.

AGE

11 y

A recheck echocardiogram is recommended in 6 months.

WEIGHT

33.5 lb

HOSPITAL NAME

Mount Olive VH

REFERRING VET

Dr. Jones



DATE

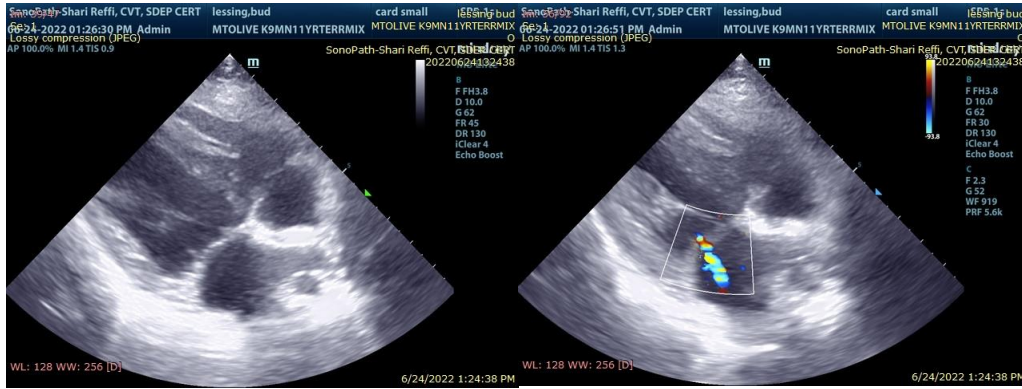
6/24/22

PERFORMED BY:

Shari Reffi, CVT

INTERPRETED BY

Keith Blass, DVM,
MS, DACVIM
(Cardiology)



The information and recommendations provided are based on the images presented by the referring veterinarian. No evaluation can be communicated regarding pathology that was not visible in the image/video clips provided.

Thank you for this referral. If the clinical or image interpretation does not parallel your findings or if I can be of any further assistance please contact me.

PATIENT

Bud Lessing

Keith Blass, DVM, MS, DACVIM (Cardiology)
KeithBlass@gmail.com
631-804-5754

SPECIES

Canine

BREED

Terrier Mix

SEX

MN

AGE

11 y

WEIGHT

33.5 lb

HOSPITAL NAME

Mount Olive VH

REFERRING VET

Dr. Jones